

Iris incarceration in an old extracapsular wound

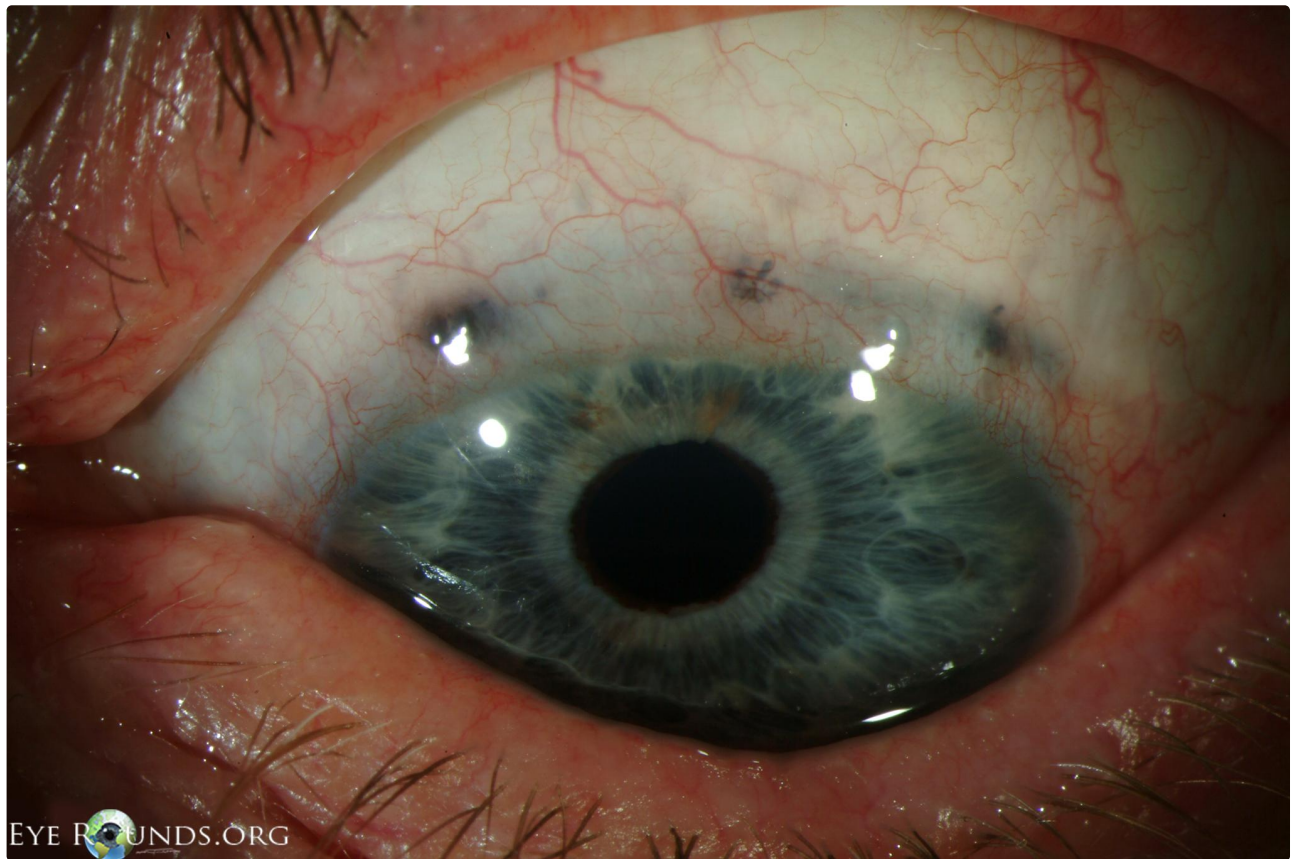
Category(ies): Cataract, Iris

Contributor: [Angela McAllister, MD](#)

Photographer: Stefani Karakas, CRA



This 73-year-old male had a complicated extracapsular cataract extraction 40 years ago for bilateral cataracts and was left aphakic. There is uveal tissue incarcerated in the old superior wound. This makes secondary intraocular lens placement difficult and potentially high risk.



 Enlarge

 Download

Image Permissions:



Ophthalmic Atlas Images by [EyeRounds.org](#), [The University of Iowa](#) are licensed under a [Creative Commons Attribution-NonCommercial-NoDerivs 3.0 Unported License](#).

Address

University of Iowa
Roy J. and Lucille A. Carver College
of Medicine
Department of Ophthalmology and
Visual Sciences
200 Hawkins Drive
Iowa City, IA 52242

[Support Us](#)

Legal

Copyright © 2019 The University of
Iowa. All Rights Reserved
[Report an issue with this page](#)
[Web Privacy Policy](#) |
[Nondiscrimination Statement](#)

Related Links

[Cataract Surgery for Greenhorns](#)
[EyeTransillumination](#)
[Gonioscopy.org](#)
[Iowa Glaucoma Curriculum](#)
[Iowa Wet Lab](#)
[Patient Information](#)
[Stone Rounds](#)
[The Best Hits Bookshelf](#)

EyeRounds Social Media

Follow



Receive notification of new cases,
[sign up here](#)
[Contact Us](#)
[Submit a Suggestion](#)